

## Enzymatic and histopathologic biomarkers as indicators of contaminant exposure and effect in Asian clam (*Potamocorbula amurensis*)

SWEE J. TEH<sup>1</sup>\*, STEPHEN L. CLARK<sup>1</sup>, CYNTHIAL. BROWN<sup>2</sup>, SAMUEL N. LUOMA<sup>2</sup> and DAVID E. HINTON<sup>1</sup>

<sup>1</sup> Department of Anatomy, Physiology, and Cell Biology, School of Veterinary Medicine, University of California-Davis, Davis, California 95616, USA

<sup>2</sup> US Geological Survey, Menlo Park, California 94025, USA

Enzymatic and histopathologic alterations of the digestive gland, gill, gonad, and kidney were studied in Asian clam (*Potamocorbula amurensis*) in April, 1997 from each of four United States Geological Survey (USGS) stations in the San Francisco Estuary. Stations were selected based on differing body burdens of metallic contaminants in clams (Stn 4.1 > 6.1 > 8.1 > 12.5) observed over 7 years. Because no pristine sites are known within the estuary and because no laboratory-reared stocks of *P. amurensis* were available, clams from station 12.5 served as reference animals. Histopathologic analysis revealed no lesions in clams collected from station 12.5. Mild digestive gland atrophy and moderate distal kidney tubular vacuolation were seen in clams collected from station 8.1. Mild digestive gland atrophy, moderate kidney tubular atrophy, and moderate gill inflammation were seen in clams collected from station 6.1. Lesions found only in clams from station 4.1 were: (1) severe inflammation and moderate atrophy of primary ducts and diverticula, and decreased numbers of heterophagosomes and heterolysosomes in diverticula of the digestive gland; (2) severe gill inflammation; (3) severe kidney tubular atrophy; (4) severe ovarian and testicular inflammation and necrosis; (5) decreased numbers of mature ova; and (6) decreased number of glycogen storage cells in the ovary and testis. Localization of specific enzymes including adenosine triphosphatase (ATP), acid phosphatase (ACP), alkaline phosphatase (ALKP), gamma-glutamyl transpeptidase (GGT), and glucose-6-phosphate dehydrogenase (G6PDH) was performed and correlated, in serial sections with glycogen (PAS) and haematoxylin and eosin stains. Enzymatic analysis revealed: (1) increased digestive diverticula ATP in stations 6.1 and 4.1; (2) decreased digestive diverticula ACP in stations 6.1 and 4.1 and proximal kidney tubular ACP deficiency in station 4.1; (3) no ALKP differences among stations; (4) increased distal kidney tubular GGT at station 12.5 and decreased distal kidney tubular GGT at station 4.1; (5) decreased digestive diverticula G6PDH in all stations except 12.5 and decreased proximal kidney tubular G6PDH in stations 8.1 and 6.1. It is possible that other anthropogenic and natural stressors may have affected the results in this study. However, the prevalence and increased severity of lesions in clams with highest metal body burden suggests a contaminant-associated etiology. Enzymatic and histopathologic biomarker alterations identified in this study were positively correlated with the metal body burden. Clams with the higher prevalence of diseases and enzyme alterations also showed a lower condition index and glycogen content in the month when histopathological assessment was performed. Further study will seek to develop enzymatic and histopathologic biomarkers for use in controlled laboratory conditions to help validate the field study.

**Keywords:** enzyme, histopathology, biomarkers, Asian clam.

### Introduction

The major emphasis in this bivalve biomarker workshop was the application and validation of biomarkers to assess toxic effects of aquatic pollutants in bivalves. The aim of this study was to characterize contaminant impacts on the Asian clam

\* Corresponding author: Swee J. Teh, Department of Anatomy, Physiology, and Cell Biology, School of Veterinary Medicine, University of California-Davis, Davis, California 95616, USA; e-mail: sjteh@ucdavis.edu

(*Potamocorbula amurensis*) at four United States Geological Survey (USGS) stations in the San Francisco Estuary by the application of enzymatic and histopathologic biomarkers. Stations were selected based on differing body burdens of various metallic contaminants in clams.

The Asian clam (*Potamocorbula amurensis*), a euryhaline species of bivalve mollusc introduced to the San Francisco Estuary in the mid-1980s, has spread so prolifically that it accounts for 95 % of the benthic invertebrate biomass in certain areas of estuary (Carlton *et al.* 1990). Between 1990 and 1998, a long term study has been conducted in the northern reach of San Francisco Bay (North Bay) which consists of monthly determinations of metal bioaccumulation, condition index, glycogen content, and population parameters in *P. amurensis* (Brown and Luoma 1995, 1998, Thompson *et al.* 1996). Brown and Luoma (1995) first demonstrated that *P. amurensis* was an effective biosentinel for studying processes controlling trace element contamination and bioavailability as well as environmental differences in trace metal exposure. Although bioaccumulation patterns of many metals are complex, tissue conditions in *P. amurensis* indicated some distinct metal contamination gradients through the North Bay (Brown and Luoma 1995). Condition index patterns are also complicated, but, in general, clams residing at the sites with highest tissue metal concentrations showed decreased glycogen content and lower condition index compared with clams at sites with lowest metal body burden concentrations. The study also indicated that the decrease of glycogen content and condition index in clams residing in areas of high metal contaminants were coincident with some changes in factors affecting population dynamics (Thompson *et al.* 1996, Brown and Luoma, unpublished data).

It should be noted that correlations between metal exposure and condition index, glycogen content, or population data alone, are not sufficient to prove metallic contaminant effects. For example, poor condition and survival of clams can also result from influences of environmental factors such as varying seasonal and year-to-year salinity, temperature, and food availability (Thompson *et al.* 1996, Parchaso *et al.* 1997). This study seeks to investigate whether enzymatic and histopathologic biomarkers can improve and verify interpretations of contaminant exposure and effects in clams when employed in combination with bioaccumulation and condition index data. The present paper is an analysis of data from a single month of sampling of four stations; later papers will more fully consider the time series data.

Histopathology has been recommended as a physiological approach to pollution investigation (Sindermann 1985). Hinton (1993) recommended this approach since it enables the researcher to examine multiple potential sites of injury rapidly and is applicable to field collection followed by examination. Histopathologic biomarkers have proven to be a valuable tool in laboratory (Meyers and Hendricks 1985, Wester and Canton 1991, Schwaiger *et al.* 1996) and field (Pierce *et al.* 1978, Malins *et al.* 1985a, b, Adams *et al.* 1989, Myers *et al.* 1994, Teh *et al.* 1997) studies. Histopathological biomarkers at the tissue level of biological organization are intermediate between molecular and individual levels (Hinton *et al.* 1992, Hinton 1997). They follow biochemical changes and resultant lesions can be observed histologically (Teh *et al.* 1997). Furthermore, histopathological alterations occur earlier than reproductive changes and are more sensitive than growth or reproduction and, as an integrative parameter, may be excellent biomarkers in correlation of environmental exposure and adverse organismal health effects (Segner and Braunbeck 1988, Hinton *et al.* 1992, Teh *et al.* 1997). Histo-

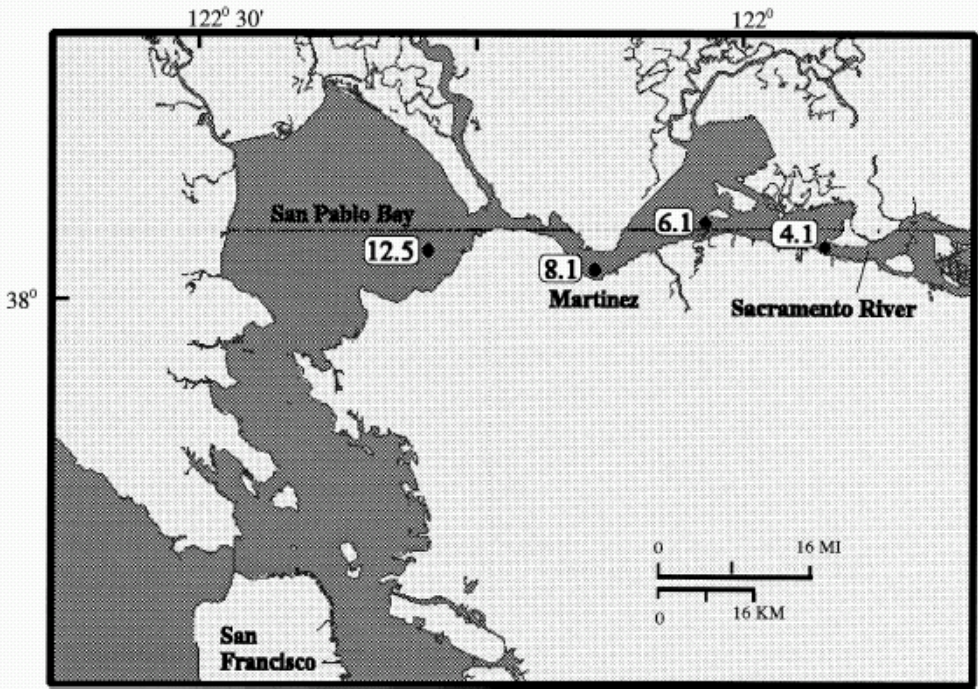


Figure 1. Map of North San Francisco bay showing sampling locations. MI = mile; KM = kilometre.

pathological biomarkers should be applied as one of a suite of biomarkers in field contaminant studies. The suite of biomarkers relate changes at one level to effects seen at other levels of biological organization (Depledge *et al.* 1995, Luoma 1996) and multiple biomarker parameters are required to provide information on the links between levels of biological organization.

## Materials and methods

### Sampling sites

Asian clams (*Potamocorbula amurensis*) were sampled aboard the USGS RV *Polaris* during the month of April 1997, at four USGS stations along a metals contaminant gradient from the lower Sacramento River down to the San Pablo Bay (figure 1). Stations 12.5 (least contaminated), 8.1, 6.1 (intermediate), and 4.1 (most contaminated) were selected based on differing body burdens of metallic contaminants in clams collected over multiple years (Brown and Luoma 1995). At each station, clams were divided into three subgroups. Groups 1 and 2 were transported back to the USGS laboratory and depurated for 48 h. Group 1 was divided into multiple size composites of 1 mm difference for metal body burden analysis as described in Brown and Luoma (1995). Condition index (defined as dry weight of visceral mass per 15 mm shell length) can be affected by the reproductive cycle and also declines in response to stress (Ringwood 1992). The index was calculated as described in Cain and Luoma (1986). Group 2 clams were analysed for glycogen content. Bivalves accumulate glycogen reserves in preparation for reproduction. They can lose their glycogen reserves in response to stress (Bayne *et al.* 1982). Group 3 was transported to the histology laboratory at ambient water temperature and processed for freeze-drying and glycomethacrylate embedment (Teh and Hinton 1993).

### Chemical analysis

Body burden analyses were determined by the method described in Brown and Luoma (1995). The total numbers of clams analysed from each site were 39 (4.1), 57 (6.1), 103 (8.1), and 40 (12.5). Clams were divided into similar length size composites (1 mm difference). The visceral mass was removed from the shell and combined within each replicate size composite. The tissue was dried, digested by reflux in concentrated nitric acid and reconstituted in 5% hydrochloric acid, then analysed by

Inductively Coupled Argon Plasma-Atomic Emission Spectroscopy (ICP-AES). The number reported for each metal concentration is the mean  $\pm$  standard deviation of the analyses of the individual size composites for each site.

To prepare the clams for glycogen analysis, the visceral masses of six clams of similar size (15–16 mm shell length) from each station were homogenized in 0.05 M TRIS buffer solution with a high speed, stainless steel tissue homogenizer, then lyophilized. Subsamples of 20 mg from each of the lyophilized samples were then analysed for glycogen content as described in Roehrig and Allred (1974). Two aliquots of each of the 20 mg samples were analysed, so that each glycogen value reported is the mean  $\pm$  standard deviation of four individual analyses.

Significant differences between means for metal and glycogen analyses were determined by ANOVA.

#### *Histopathology and histochemistry*

Visceral masses of clams (five clams per station) were processed for freeze-drying and glyco-methacrylate embedment as described in Teh and Hinton (1993). Seven slides per block of clams and two sections per slide were serially sectioned at 5  $\mu$ m thickness. The first was stained in Mayer's alum haematoxylin (H) and 1 % aqueous eosin Y (E) for histopathologic examination. Slides 2–7 were reacted at room temperature for localization of glycogen with periodic acid–Schiff reagent (PAS), acid phosphatase (ACP), alkaline phosphatase (ALKP), adenosine triphosphatase (ATP), gamma-glutamyl transpeptidase (GGT), and glucose-6-phosphate dehydrogenase (G6PDH). Details of each enzyme protocol are described in Teh and Hinton (1993). To reduce bias, codes for individual station of collections were not broken until completion of the final histochemical and histopathological examinations.

Because no pristine sites are known within the estuary and because no laboratory-reared stocks of *P. amurensis* were available, clams from station 12.5 with the lowest metal body burden served as reference animals in this study. The severity of the enzymatic and histopathologic alterations were semi-quantitatively ranked based on the cytological alterations found in each clam. Enzymatic rankings were: -1 = decreased in staining reactions, 0 = normal staining reactions, 1 = increased staining reactions. Histopathological rankings were: 0 = no pathological alteration, 1 = minimal pathological alterations, 2 = moderate pathological alterations, 3 = severe pathological alteration.

## **Results and Discussion**

### *Body burden, biochemical and individual analyses*

Trace metals are of biological interest because of their role as micronutrients and toxicants. The trace metals of most concern for studies of the effect of contaminants, based on the body burden analysis in this study, include cadmium, chromium, copper, nickel, and zinc (figure 2). High concentrations of trace metals can result in enzyme stimulatory or inhibitory responses under acute exposures. However, chronic exposures, which are more relevant to real world scenarios, cause some far more interesting effects. Due to the complexity of the estuary, it is not the intent of this study to discuss the mechanistic and toxicologic effects of metals on this aquatic organism. Interested readers should consult reviews on metal toxicity in bivalves (Phillips 1977, Luoma 1983, Rainbow 1993).

Trace metals enter the San Francisco Estuary from a wide variety of sources, including urban and agricultural runoff, industrial effluents, old mines, and from weathering of soils and rocks within the watershed; thus metal bioaccumulation patterns are complicated. Nevertheless, Asian clams collected during April 1997 showed data on body burden of metals resembling patterns that were commonly found in the multi-year monitoring study described by Brown and Luoma (1995) in this estuary. The concentrations of metals in the whole clam tissues collected from the four stations are shown in figure 2. Except for silver (Ag), significantly higher levels of nickel (Ni), vanadium (V), cadmium (Cd), zinc (Zn), copper (Cu), and chromium (Cr) were found at stations 4.1 and 6.1 than at stations 8.1 and 12.5. In contrast, significantly lower condition index and glycogen content are found at stations 4.1 and 6.1 compared with stations 8.1 and 12.5 (figure 3). Thus, the results of this 1 month of data agree with a more general pattern in the longer term bioaccumulation study that shows that clams with the highest metal body burden

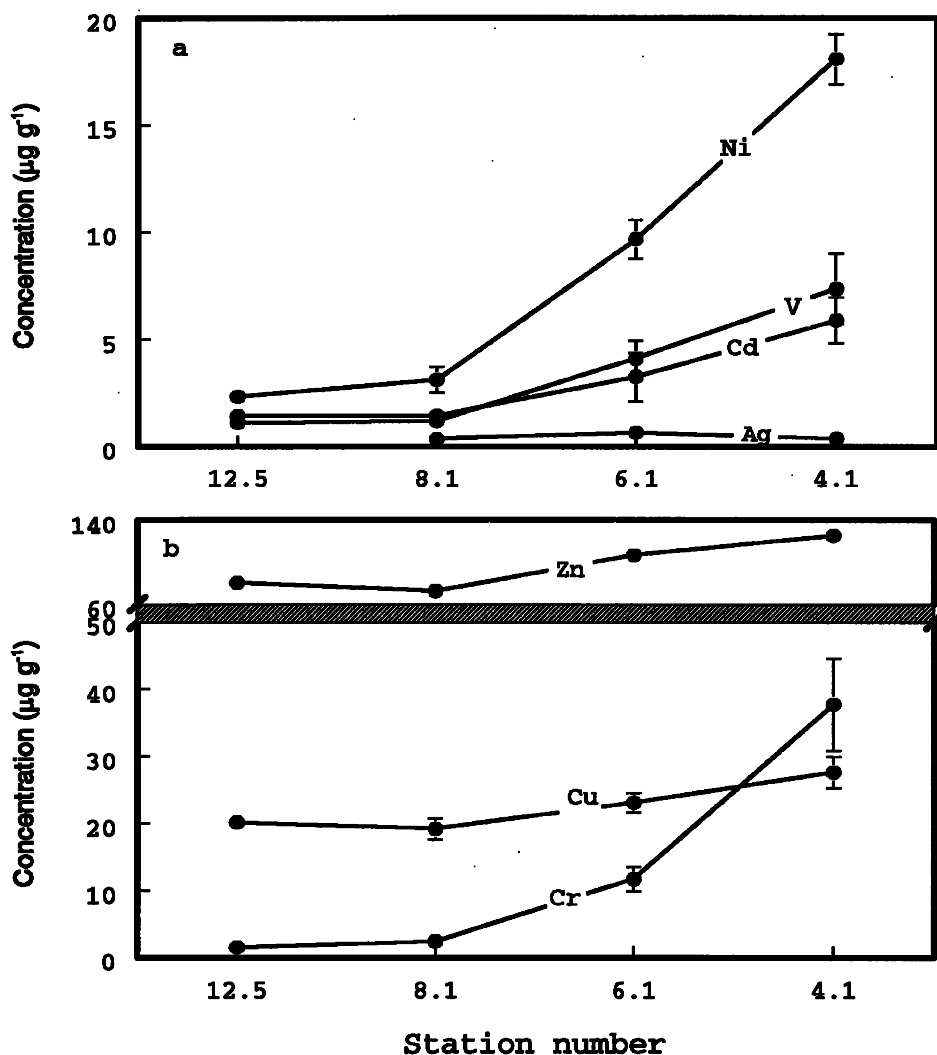


Figure 2. (a) Ag, Cd, V and Ni concentrations and (b) Cr, Cu and Zn concentrations ( $\mu\text{g g}^{-1}$ ) in whole soft tissue of *Potamocorbula amurensis* collected at the four USGS sites in April 1997. Error bars represent standard deviation.

often have the lowest condition index and glycogen content (Brown and Luoma, USGS, unpublished).

### Histopathology

Semi-quantitative histopathologic analysis revealed no lesions in clams collected from station 12.5. Clams collected from this station show abundant glycogen storage cells in the ovary (figures 4a and 4b) and testis (figures 4c and 4d). Gill, kidney, digestive gland and skeletal muscle morphology were in normal condition. In clams collected from station 8.1, mild digestive gland atrophy and moderate distal kidney tubular vacuolation were seen. Mild digestive gland atrophy, moderate kidney tubular atrophy, and moderate gill inflammation were seen in clams collected from station 6.1. Lesions found only in clams from station 4.1 were: (1) severe inflammation and moderate atrophy of primary ducts and diverticula,



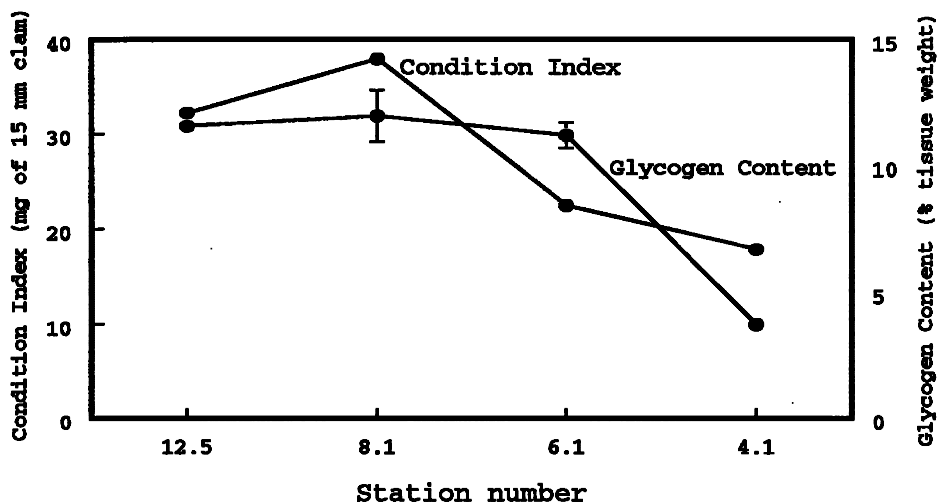


Figure 3. Condition index (mg dry weight of tissue of a 15 mm shell length) and glycogen content (% tissue weight) of *Potamocorbula amurensis* collected at the four USGS sites in April 1997. Error bars for glycogen data represent standard deviation.

and decreased numbers of heterophagosomes and heterolysosomes in diverticula of the digestive gland; (2) severe gill inflammation; (3) severe kidney tubular atrophy; (4) severe ovarian (figure 4e) and testicular (figure 4f) inflammation and necrosis; (5) decreased numbers of mature ova (figure 4e); (6) decreased number of glycogen storage cells in the ovary (figure 4e) and testis (figure 4f).

When stained for PAS, glycogen storage cells were prominent in all clams collected from station 12.5 and 8.1 (figures 4b and 4d). Reductions in numbers of glycogen storage cells were seen in clams with highest metal body burden at station 4.1 (figures 4e and 4f). These reductions in glycogen storage cells were also associated with an apparent increase in ovarian necrosis and inflammation (figure 4e) and testicular necrosis and inflammation (figure 4f). Thus, increases in prevalence of lesions corresponded with the increased metal body burden, decreased glycogen content and condition index.

Because of their ability to bioaccumulate dissolved trace metals and store them for a long period in their tissues, bivalves have been suggested as an animal model in biomonitoring programmes investigating marine pollution. Yevich and Yevich (1994) reported kidney as the target organ for cadmium toxicity in over 26 marine species under laboratory exposure; but they rarely found a similar kidney condition in the field monitoring studies where cadmium was detected. Bioaccumulation of trace metals varies greatly between invertebrates; and within an organism variation between different organs was seen (Rainbow 1993). Thus organ-specific toxic effects are probably related to uptake and elimination rates, concentrations of accumulated trace metals, and/or differences in sensitivity of target organs. The above may have as much or more effect than do differences in concentrations of trace metals between field sites. The higher prevalence of digestive gland, gill, kidney, ovarian and testicular alterations in clams from highest metal body burden suggested that these organs may be the principal metal accumulating organs and hence the target organs for metal toxicity. We do not know which metal or combination of metals induced such organ-specific toxic effects in clams of this study. An extensive laboratory experimental exposure is needed to verify targets of specific metals.

### Histochemistry

Freeze-dried glycolmethacrylate embedment and enzyme- and immuno-histochemistry protocols have been developed and applied in our laboratory (Teh and Hinton 1993) and we recommend these for field studies (Hinton *et al.* 1992). The early detection of an enzyme abnormality provides an indication that metabolic pathways have been altered and the technique localizes the apparent alteration to specific affected cells.

Enzyme histochemical analyses revealed, in visual observations by light microscopy, that reaction products for various enzymes were: (1) increased in digestive diverticula for ATP in stations 6.1 and 4.1 over station 12.5; (2) decreased in digestive diverticula for ACP in stations 6.1, 4.1, and decreased in proximal kidney tubular epithelium at station 4.1 over station 12.5; (3) no ALKP changes were seen among stations; (4) increased in distal kidney tubular epithelial reaction for GGT at station 12.5 but decreased in distal kidney tubular GGT at station 4.1; and finally (5) decreased in digestive diverticula G6PDH in all stations except 12.5 with decreased proximal kidney tubular G6PDH in stations 8.1 and 6.1.

Except for GGT, the enzymes chosen are all metal-containing or -dependent enzymes. Therefore, the data suggest that the changes in enzyme reactivity are due to toxicity of metals. The uptake of plasma glutathione, an antioxidant enzyme, is catalysed by GGT (Stenius and Hogberg 1988). This enzyme is associated with cytochrome P450 and is important in reducing and eliminating certain toxic metabolites. GGT reaction was increased in the distal kidney tubular epithelium at station 12.5 (figure 5a) but decreased reactions were seen in clams collected from stations 6.1 and 4.1 (figure 5b). Comparison of serial sections of digestive glands between clams collected from stations 12.5 and 4.1 reacted for different enzymes are shown in figures 6a–6f. In these figures, digestive gland of clams exposed to lowest concentrations of metals showed higher reactivities of ACP (figure 6a), GGT (figure 6c), and G6PDH (figure 6e). Conversely, digestive glands of clams exposed to highest concentrations of metals show lower reactivities of ACP (figure 6b), GGT (figure 6d), and G6PDH (figure 6f).

Metal metabolism has significant effects on metal accumulation and distribution in the tissues and the toxic effects of metals are related to the level and duration of exposure (Hodson 1988). The major action of toxic metals is the inhibition of enzymes. This occurs either through the interaction between metal and the SH group or by displacement of an essential metal cofactor of the enzyme. The decreased reactivities of G6PDH in clams with higher concentrations of metals are most likely related to the displacement of magnesium cofactor by cadmium, copper or other metals such that the enzyme lost sensitivity to magnesium activation. Similar effects may have also happened with ACP and GGT in this study.

### Summary and conclusions

Previous data have shown that clams with the highest metal body burden have the lowest condition index and glycogen content (Brown and Luoma, unpublished data). In addition, differences in population dynamics were observed between stations of highest metal body burden and lowest metal body burden. Asynchrony in spawning occurred at the three locations with the highest cadmium content. Therefore, cadmium content may be an important factor in determining reproductive periodicity and synchrony (Thompson *et al.* 1996, Parchaso *et al.*

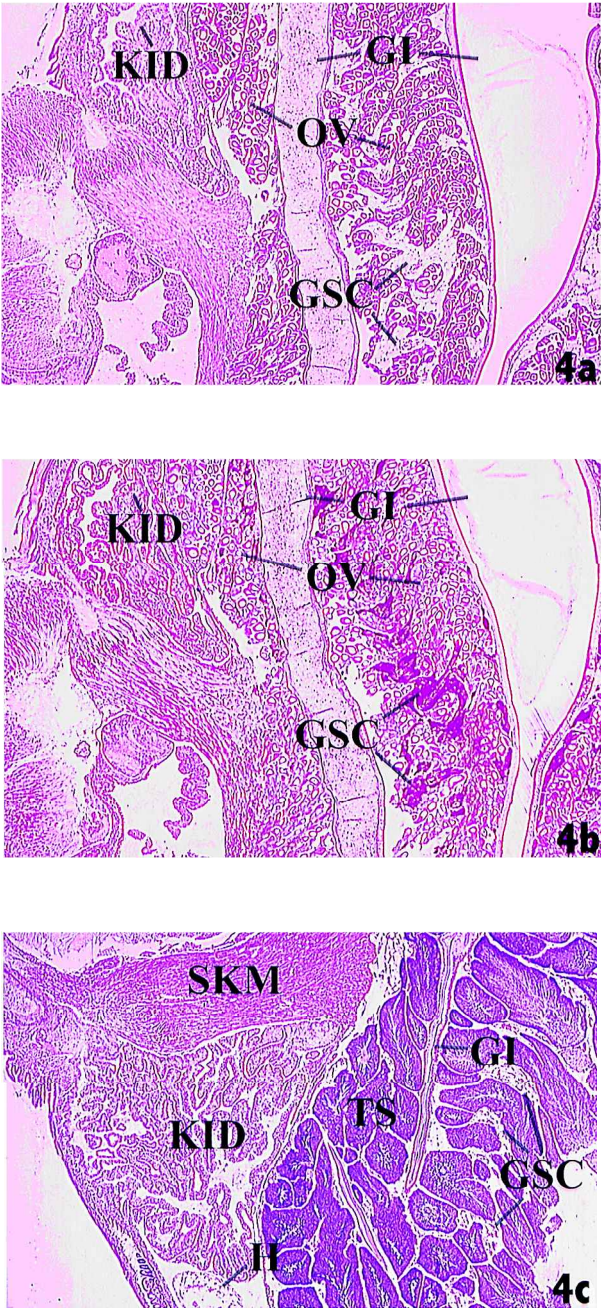
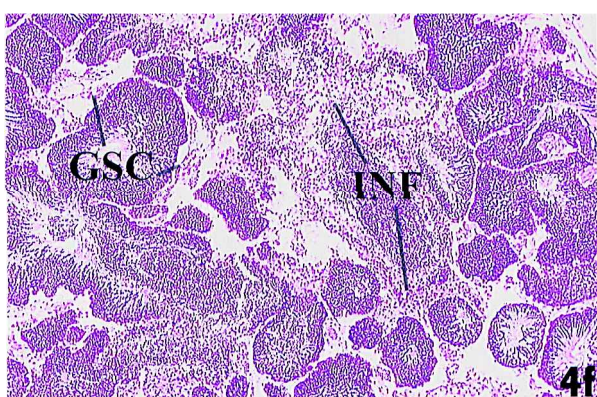
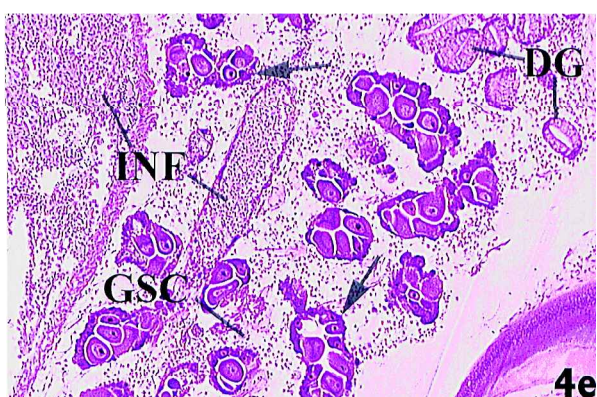
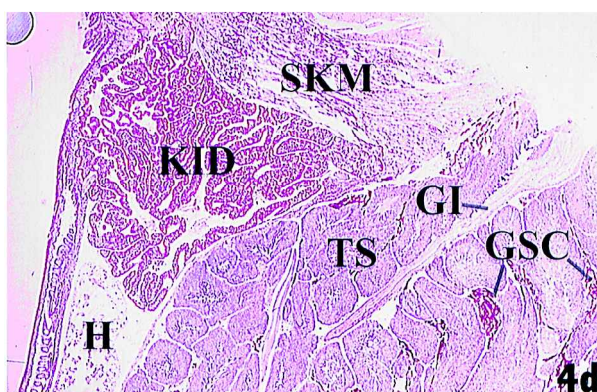


Figure 4.  
4a and 4b: Freeze-drying and glycolmethacrylate embedment (FDGE) sections of female *Potamocorbula amurensis* collected from station 12.5. 4a: Normal morphology of glycogen storage cells (GSC), intestine (GI), kidney (KID), and ovary (OV) was seen. H and E.  $\times 30$ . 4b: Serial section stained for PAS revealed enhanced staining in glycogen storage cells, kidney, and ovary. PAS.  $\times 30$ .  
4c and 4d: FDGE sections of male *Potamocorbula amurensis* collected from 12.5. 4c: Normal morphology of glycogen storage cells (GSC), heart (H), intestine (GI), skeletal muscle (SKM), kidney (KID), and testis (TS) was seen. H and E.  $\times 30$ . 4d: Serial section stained for PAS revealed enhanced staining in glycogen storage cells and kidney. PAS.  $\times 30$ .





4e and 4f: FDGE sections of *Potamocorbula amurensis* collected from station 4.1. 4e: Severe ovarian necrosis and inflammation (INF). Decreased number of glycogen storage cells (GSC) and increased number of immature ova (arrows) were seen in this section. When serial section of this clam reacted for PAS (not shown), decreased number of positive GSC was noted. DG = digestive gland. H and E.  $\times 75$ . 4f: Severe testicular necrosis and inflammation (INF). When serial section of this clam was reacted for PAS (not shown), decreased number of positive GSC was also noted. H and E.  $\times 75$ .

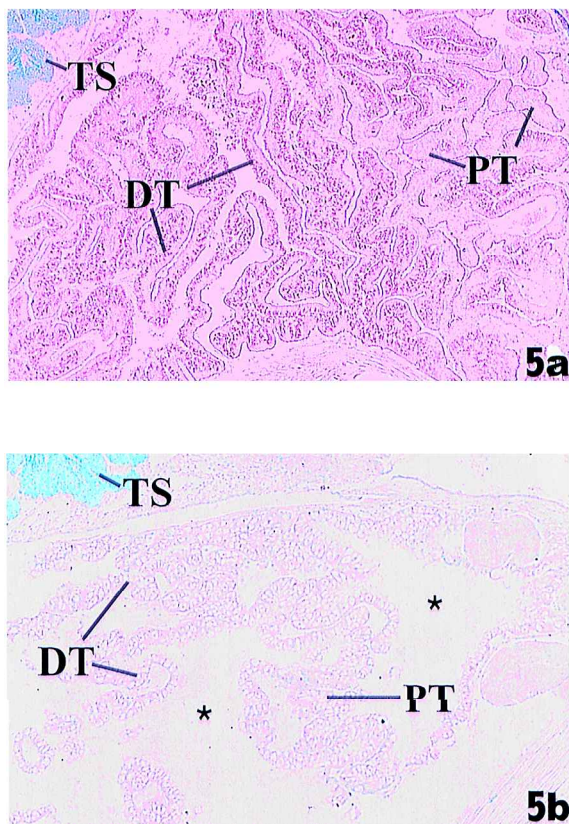


Figure 5. FDGE sections of *Potamocorbula amurensis* kidney reacted for GGT. 5a: Strong GGT positive reactions in distal tubular epithelia cells (DT) and normal positive reactions in proximal tubular epithelia cells (PT) were seen in clam collected from station 12.5. TS = testis. GGT.  $\times 150$ . 5b: No GGT reactions were seen in kidney of clam collected from station 4.1. Severe tubular oedema was seen in the whole kidney (\*). TS = testis. GGT.  $\times 150$ .

1997). Although it is possible that other anthropogenic and natural stressors not measured in this study may have contributed to the histopathological and histochemical alterations, the prevalence and increased severity of lesions in clams with the highest metal body burden suggests a contaminant-associated aetiology. Alterations in enzymatic reactivities and increases in prevalence and severity of histopathologic biomarkers in clams tended to align with increasing with body burdens of metals. Clams with lower condition index and glycogen content have a higher incidence of diseases and enzyme alterations. Thompson *et al.* (1996) showed altered reproductive status in these stressed populations. Thus, this study has succeeded in circumstantially linking disruption of processes associated with population dynamic conditions (reproduction) to increased metallic body burden using enzymatic and histopathological biomarkers as indicators of both environmental exposure and deleterious effects. Enzymatic and histopathological biomarkers, when applied in combination with other biomarkers at lower and upper levels of biological organization, can be a critical link for associating exposure responses to ecological effects in a complex aquatic ecosystem.

Participants of the workshop were asked to address a series of questions (see introductory paper by Ringwood, A. H., Hameedi, M. J., Lee, R. F., Brouwer, M.,



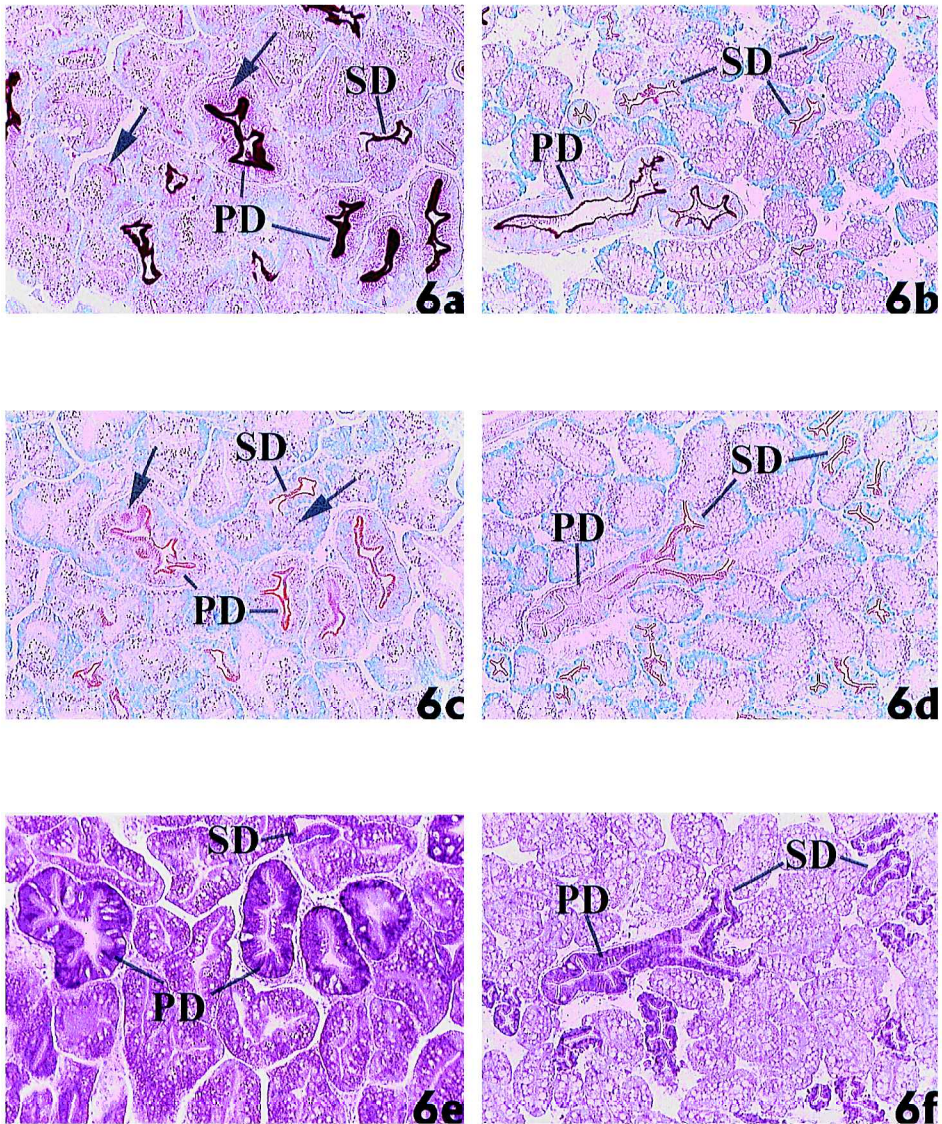


Figure 6. Comparison of serial FDGE sections of *Potamocorbula amurensis* digestive gland collected from station 12.5 and 4.1. 6a, 6c, 6e:  $\times 150$ . Serial section of digestive gland from station 12.5 showing reactivity for ACP (6a), GGT (6c), and G6PDH (6e). All three enzymes were reacted strongly in the primary (PD) and secondary (SD) ducts of the digestive gland. Enhanced cytoplasmic ACP, GGT, and G6PDH positive reactions were also seen in the digestive diverticulum. 6b, 6d, 6f:  $\times 150$ . Serial section of digestive gland from station 4.1 showing reactivity for ACP (6b), GGT (6d), and G6PDH (6f). When compared with station 12.5, decreased primary (PD) and secondary (SD) ducts and cytoplasmic lysosomal ACP reactions were seen (6b). No changes in the secondary duct GGT reaction, but decreased or diminished GGT reactions were seen in primary duct and diverticulum (6d). Digestive gland from station 4.1 showed decrease G6PDH reactions in the digestive diverticulum when compared with station 12.5. (6f).

Peters, E. C., Scott, G. I., Luoma, S. N. and R. T. DiGiulio. Bivalve Biomarker Workshop: Overview and Discussion Group Summaries, this volume). What follows are answers to those questions.

The importance of histopathological biomarkers is their ability to distinguish

between infectious disease or natural environmental factor-induced alterations from those of contaminant-induction. Therefore, certain histopathological biomarkers indicate prior contaminant(s) exposure and function best as general indicators of health of the organisms. Tissue and organ damage are potentially related to reproductive output so histopathological effects can reflect both exposure and effects. This is shown in our results where higher prevalence of ovarian and testicular alterations was seen in clams with the highest metal body burden. Chronic responses that reflect irreversible damage may be distinguishable from transient effects, but could require long-term biomonitoring. Specific host cellular responses may also provide evidence as to timing of exposure and effect. Because of the small sample size (five clams per site) in this study, no statistical analyses were done to document the relationship between biomarker response and chemical contaminant concentrations. However, when additional data are available, this apparent correlation will be tested statistically.

It is postulated from the results of this study that changes in population dynamics are related to increases in metal body burden, increases in ovarian and testicular necrosis, decreases in condition index and glycogen content, and decreases in reproductive output. Future field studies will seek to examine more clams at each site, employ multivariate statistical analyses, and look at the effects of natural environmental variables on the biomarker responses examined to more accurately link biomarker response and fitness.

## Acknowledgments

This work was supported by the US Environmental Protection Agency (USEPA) grants R 825298 and USEPA Center for Ecological Health Research at UC Davis grants CR 819658. Although the information in this document has been funded wholly or in part by the USEPA, it may not necessarily reflect the views of the Agency and no official endorsement should be inferred.

## References

- ADAMS, S. M., SHEPARD, K. L., GREELEY, J. M. S., JIMENEZ, B. O., RYON, M. G., SHUGART, L. R. and MCCARTHY, J. F. 1989, The use of bioindicators for assessing the effects of pollutant stress on fish. *Marine Environmental Research*, **28**, 459–464.
- BAYNE, B. L., BUBEL, A., GABBOTT, P. A., LIVINGSTONE, D. R., LOWE, D. M. and MOORE, M. N. 1982, Glycogen utilisation and gametogenesis in *Mytilus edulis* L. *Marine Biology Letters*, **N3**, 89–105.
- BROWN, C. L. and LUOMA, S. N. 1995, Use of the euryhaline bivalve *Potamocorbula amurensis* as a biosentinel species to assess trace metal contamination in San Francisco Bay. *Marine Ecology Progress Series*, **124**, 129–142.
- BROWN, C. L. and LUOMA, S. N. 1998, Metal trends and effects in *Potamocorbula amurensis* in North San Francisco Bay. *Interagency Ecological Program Newsletter*, **11**, N2: 33–35.
- CAIN, D. J. and LUOMA, S. N. 1986, Effect of seasonally changing tissue weight on trace metal concentrations in the bivalve *Macoma balthica* in San Francisco Bay. *Marine Ecology Progress Series*, **28**, 209–217.
- CARLTON, J. T., THOMPSON, T. K., SCHEMEL, L. E. and NICHOLS, F. H. 1990, Remarkable invasion of San Francisco Bay (California, USA) by Asian clam *Potamocorbula amurensis*. I. Introduction and dispersal. *Marine Ecology Progress Series*, **V66**, N1–2, 81–94.
- DEPLEDGE, M. H., AAGAARD, A. and GYORKOS, P. 1995, Assessment of trace metal toxicity using molecular, physiological and behavioural biomarkers. *Marine Pollution Bulletin*, **31**, N1–3, 19–27.
- HINTON, D. E. 1993, Cells, cellular responses, and their markers in chronic toxicity of fishes. In: *Aquatic Toxicology: Molecular, Biochemical and Cellular Perspectives*, D. C. Malins and G. K. Ostrander, eds (Boca Raton, Florida: Lewis Publishers), pp. 207–239.
- HINTON, D. E. 1997, Histologic responses, signifying exposure or effect and their application to aquatic



- ecotoxicology. In: *Ecotoxicology: Responses, Biomarkers, & Risk Assessment, an OECD Workshop*, SOS publications, J. T. Zelikoff, ed. (Fair Haven, New Jersey), pp. 293–309.
- HINTON, D. E., BAUMANN, P. C., GARDNER, G. R., HAWKINS, W. E., HENDRICKS, J. D., MURCHELANO, R. A. and OKIHIRO, M. S. 1992, Histopathologic biomarkers. In: *Biomarkers*, R. J. Huggett, R. A. Kimerle, P. M., Jr. Mehrle and H. L. Bergman, eds (Boca Raton, Florida: Lewis Publishers), pp. 155–211.
- HODSON, P. V. 1988, The effect of metal metabolism on uptake, disposition and toxicity in fish. *Aquatic Toxicology*, **11**, 3–18.
- LUOMA, S. N. 1983, Bioavailability of trace metals to aquatic organisms—a review. *Science of the Total Environment*, **28**, 1–22.
- LUOMA, S. N. 1996, The developing framework of marine ecotoxicology: pollutants as a variable in marine ecosystems? *Journal of Experimental Marine Biology and Ecology*, **200**, 29–55.
- MALINS, D. C., KRAHN, M. M., MYERS, M. S., RHODES, L. D., BROWN, D. W., KRONE, C. A., MCCAIN, B. B. and CHAN, S. L. 1985a, Toxic chemicals in sediments and biota from a creosote-polluted harbor: relationships with hepatic neoplasms and other hepatic lesions in English sole (*Parophrys vetulus*). *Carcinogenesis*, **6**, 1463–1469.
- MALINS, D. C., KRAHN, M. M., BROWN, D. W., RHODES, L. D., MYERS, M. S., MCCAIN, B. B. and CHAN, S. L. 1985b, Toxic chemicals in marine sediment and biota from Mukilteo, Washington: relationships with hepatic neoplasms and other hepatic lesions in English sole (*Parophrys vetulus*). *Journal of the National Cancer Institute*, **74**, 487–494.
- MEYERS, T. R. and HENDRICKS, J. D. 1985, Histopathology. In: *Fundamentals in Aquatic Toxicology*, G. M. Rand and S. R. Petrocelli, eds (Washington, DC: Hemisphere) pp. 283–331.
- MYERS, M. S., STEHR, C. M., OLSON, O. P., JOHNSON, L. L., MCCAIN, B. B., CHAN, S. L. and VARANASI, U. 1994, Relationship between toxicopathic hepatic lesions and exposure to chemical contaminants in English sole (*Plauconectes vetulus*), starry flounder (*Platichthys stellatus*) and white croaker (*Genyonemus lineatus*) from selected marine sites on the Pacific Coast, USA. *Environmental Health Perspectives*, **102**, 200–215.
- PARCHASO, F., BROWN, C. L., THOMPSON, J. K. and LUOMA, S. N. 1997, *In situ* effects of trace contaminants on the ecosystem in the San Francisco Bay estuary, 1995: the necessary link to establishing water quality standards II. *US Geological Survey Open File Report* 97–420.
- PHILLIPS, D. J. H. 1977, The use of biological indicator organisms to monitor trace metal pollution in marine and estuarine environments—a review. *Environmental Pollution*, **13**, 281–317.
- PIERCE, K. V., MCCAIN, B. B. and WELLINGS, S. R. 1978, Pathology of hepatomas and other liver abnormalities in English sole (*Parophrys vetulus*) from the Duwamish River estuary, Seattle, Washington. *Journal of the National Cancer Institute*, **60**(6), 1445–1453.
- RAINBOW, P. S. 1993, *Ecotoxicology of Metals in Invertebrates*, R. Dallinger and P. S. Rainbow, eds (Boca Raton, Florida: Lewis Publishers), pp. 3–23.
- RINGWOOD, A. H. 1992, Effects of chronic cadmium exposures on growth of larvae of an Hawaiian bivalve, *Isognomon californicum*. *Marine Ecology Progress Series*, **83**, 63–70.
- ROEHRIG, K. L. and ALLRED, J. B. 1974, Direct enzymatic procedure for the determination of liver glycogen. *Analytical Biochemistry*, **58**, 414–421.
- SCHWAIGER, J. K., FENT, H., STECHER, H., FERLING, H. and NEGELE, R. D. 1996, Effects of sublethal concentrations of triphenyltinacetate on rainbow trout (*Oncorhynchus mykiss*). *Archives of Environmental Contamination and Toxicology*, **30**, 327–334.
- SEGNER, H. and BRAUNBECK, T. 1988, Hepatocellular adaptation to extreme nutritional conditions in ide, *Leuciscus idus melanotus* L. (cyprinidae). A morphofunctional analysis. *Fish Physiology and Biochemistry*, **5**, 79–97.
- SINDERMAN, C. J. 1985, Keynote address: Notes of a pollution watcher. In: *Marine Pollution and Physiology: Recent Advances*, F. J. Vernberg F. P. Thurberg, A. Calabrese and W. Vernberg, eds (Columbia: University of South Carolina Press), pp. 11–30.
- STENIUS, U. and HOGBERG, J. 1988, Gamma-glutamyltranspeptidase-conferred resistance to hydroquinone induced GSH depletion and toxicity in isolated hepatocytes. *Carcinogenesis*, **9**, 1223–1227.
- TEH, S. J. and HINTON, D. E. 1993, Detection of enzyme histochemical markers of hepatic preneoplasia and neoplasia in medaka (*Oryzias latipes*). *Aquatic Toxicology*, **24**, 163–182.
- TEH, S. J., ADAMS, S. M. and HINTON, D. E. 1997, Histopathologic biomarkers in feral freshwater fish populations exposed to different types of contaminant stress. *Aquatic Toxicology*, **37**, 51–70.
- THOMPSON, J. K., PARCHASO, F., BROWN, C. L. and LUOMA, S. N. 1996, *In situ* ecosystem effects of trace contaminants in the San Francisco Bay estuary: the necessary link to establishing water quality standards. *US Geological Survey Open File Report* 96–437.
- WESTER, P. W. and CANTON, J. H. 1991, The usefulness of histopathology in aquatic toxicity studies. *Comparative Biochemistry and Physiology*, **100C**, 115–117.
- YEVICH, P. P. and YEVICH, C. A. 1994, Use of histopathology in biomonitoring marine invertebrates, *Biomonitoring of Coastal Waters and Estuaries*, K. J. M. Kramer, eds. (Boca Raton, Florida: CRC Press), pp. 179–192.